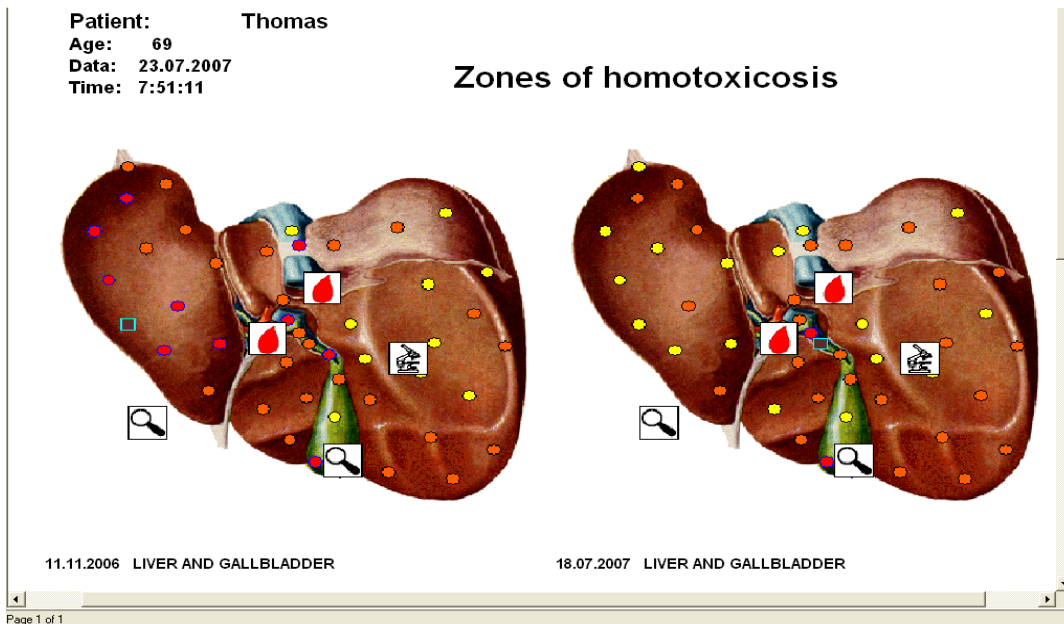
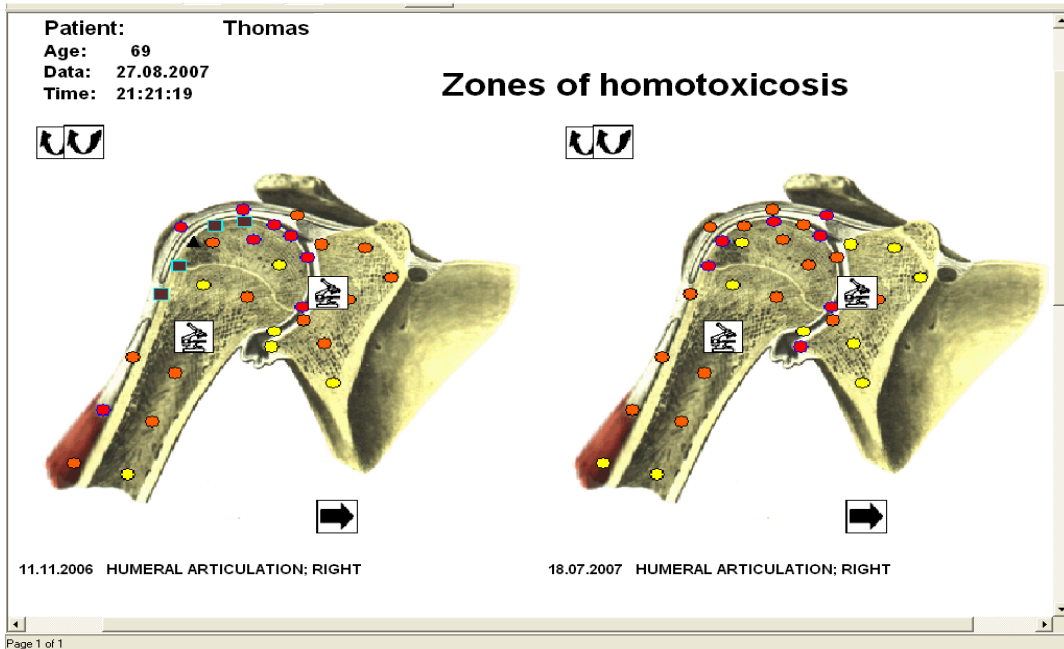


## HEALTH DETECTOR SCAN RESULTS TYPICAL PRINTOUT

A case of 69 y.o. male patient with the right shoulder joint osteoarthritis and dyslipidemia (currently on the long-term liver affecting treatment with statins) before and after the course of anti-homotoxic therapy:



### Designation for Homotoxicosis Phases:



Reserve ideal tissue (stem cells)



Actively functioning tissue – toxins excreted



Fatigued tissue with toxin deposition  
Inflammation



Homeostasis deformation. Cell damaging toxins impregnation. Chronic and latent illnesses



Homeostasis disturbance. Target organ appearance. Functional imbalance. Degenerative diseases



Homeostasis destruction. Structural changes in tissues. Foreign bodies or neoplasm